

# Intrauterine Fluid Instillation and Transtubal Flow: A Randomized Controlled *In vitro* Trial Comparing Gel and Water

Soetkin G. Thijssen<sup>1</sup>, Ruben R. G. Heremans<sup>1</sup>, Meri Nderlita<sup>1</sup>, Wouter J. G. Froyman<sup>1</sup>, Susanne Housmans<sup>1</sup>, Willy A. J. Poppe<sup>1</sup>, Dirk Timmerman<sup>1</sup>, Thierry Van den Bosch<sup>1,2\*</sup>

<sup>1</sup>Department of Obstetrics and Gynaecology, University Hospitals KU Leuven, Leuven, <sup>2</sup>Department of Obstetrics and Gynaecology, RZ Tienen, Tienen, Belgium

## Abstract

**Background:** Possible transtubal spillage of malignant cells is a major concern in fluid instillation sonography, as it is in hysteroscopy. This study aims to compare the transtubal flow of gel and saline and validate the clinical hypothesis that application of fluids with higher viscosity causes less spillage. **Methods:** Randomized controlled *in vitro* trial comparing gel and saline infusion on 15 tissue specimens after hysterectomy with bilateral salpingectomy. Instillations are performed with saline and gel dyed with a 1% ink solution. Qualitative assessment of tubal spill is investigated as primary outcome. Secondary outcomes are instillation-volume and -pressure, assessed by measuring endometrial cavity dilation at *in vitro* ultrasound examination and subjective numeric 10-point scoring of the instillation pressure by a dedicated examiner. **Results:** Tubal flow was more often observed during saline instillation (odds ratio 4.88,  $P = 0.008$ ). Median subjectively assessed instillation pressures were nine arbitrary units for gel and three for saline ( $P < 0.001$ ). Tubal flow occurred from 2 cc onward in the saline group versus five cc in the gel instillation group. Cavitary dilation did not differ between both groups. **Conclusion:** Gel instillation sonography is *in vitro* associated with less tubal flow and therefore could be a safer diagnostic test compared to saline infusion sonography or hysteroscopy. *In vivo* studies are necessary to confirm these results.

**Keywords:** Diagnosis, endometrial cancer, endometrium, sonohysterography, transtubal flow, ultrasound

## INTRODUCTION

Ultrasonography and contrast sonohysterography are used to select patients at risk for benign and malignant intracavitary lesions. Contrast sonography was originally performed by instilling saline solution and was called saline contrast sonohysterography or saline infusion sonography.<sup>[1]</sup> Recently, the gel has been proposed as an alternative to saline: gel instillation sonography.<sup>[2-5]</sup>

In 2009, a prospective observational cohort study, comparing saline infusion sonography and gel instillation sonography, showed no difference in technical feasibility nor diagnostic accuracy, while the reported procedure-related pain was less in the gel instillation sonography group.<sup>[3]</sup>

In comparison with saline, gel also has some additional physical advantages owing to its higher viscosity: less backflow

through the cervix, a more stable filling of the uterine cavity and consequently, a smaller required instillation volume.<sup>[3]</sup>

Malignant lesions may be missed using blind sampling, by office sampling or dilatation and curettage.<sup>[6]</sup>

It is, therefore, recommended to combine sampling with imaging (hysteroscopy or contrast ultrasound) to prevent false-negative results. Hysteroscopy, saline infusion sonography, and gel instillation sonography are equally accurate in the triage of patients at risk for endometrial cancer in whom the histological examination is needed.<sup>[3,4,7,8]</sup> However, the costs of an intraoperative hysteroscopy in comparison with

**Address for correspondence:** Dr. Thierry Van den Bosch, Department of Obstetrics and Gynaecology, University Hospitals Gasthuisberg KU Leuven, Herestraat 49, 3000, Leuven, Belgium. E-mail: [thierry.vandenbosch@uzleuven.be](mailto:thierry.vandenbosch@uzleuven.be)

Received: 01-04-2019 Revised: 01-05-2019 Accepted: 07-05-2019 Available Online: 06-09-2019

### Access this article online

#### Quick Response Code:



Website:  
[www.jmuonline.org](http://www.jmuonline.org)

DOI:  
10.4103/JMU.JMU\_29\_19

This is an open access journal, and articles are distributed under the terms of the Creative Commons Attribution-NonCommercial-ShareAlike 4.0 License, which allows others to remix, tweak, and build upon the work non-commercially, as long as appropriate credit is given and the new creations are licensed under the identical terms.

**For reprints contact:** [reprints@medknow.com](mailto:reprints@medknow.com)

**How to cite this article:** Thijssen SG, Heremans RR, Nderlita M, Froyman WJ, Housmans S, Poppe WA, *et al.* Intrauterine fluid instillation and transtubal flow: A randomized controlled *in vitro* trial comparing gel and water. *J Med Ultrasound* 2020;28:35-40.

saline infusion sonography and gel instillation sonography are higher.<sup>[9,10]</sup>

It has already been proven that, in case of endometrial cancer, seeding of malignant cells from the uterine cavity into the abdominal cavity occurs during hysteroscopy as well as during saline infusion sonography.<sup>[11-14]</sup> Despite the association between hysteroscopy/saline infusion sonography and positive peritoneal cytology, it has not yet been demonstrated that this seeding of cancer cells results in peritoneal metastasis, disease recurrence, or poorer prognosis.<sup>[15]</sup> However, out of precaution, hysteroscopy guidelines advocate to use the least intrauterine pressure and the smallest volume necessary to achieve the diagnosis.<sup>[16,17]</sup>

It is believed that the higher the instillation rates and the lower the fluid viscosity, the more transtubal flow is to be expected. Therefore, transtubal spillage is thought to be less likely with gel instillation sonography than with saline instillation sonography.<sup>[4]</sup> However, currently, no prospective studies have been done to confirm this hypothesis.

The aim of this prospective study is to examine whether there is less transtubal flow with gel instillation sonography than with saline infusion sonography.

## SUBJECTS AND METHODS

This study was designed as a monocentric randomized controlled *in vitro* trial on hysterectomy specimens conducted at the Department of Obstetrics and Gynaecology of the University Hospitals Leuven, Belgium.

We intended to include 20 patients because this is an explorative study and we assumed a significant difference after the inclusion of 20 persons.

Patients were eligible for inclusion if they were of at least 18 years of age, mentally competent and if they were scheduled for a hysterectomy with bilateral salpingectomy or with bilateral salpingo-oophorectomy. The exclusion criteria were a history of sterilization or previous bilateral salpingectomy, visible damage on the integrity of the uterine cavity and/or tubes, and malignancy.

The study was approved by the Ethics Committee of the University Hospitals Leuven (S60115). Experimental procedures followed the ethical standards for experimentation on humans declared by the 1975 Declaration of Helsinki. Written informed consent was obtained in all patients.

For the randomization, a random integer generator (<https://www.random.org>) was used to generate 20 random integers (one: first saline or two: first gel). A third person, who did not participate in the study, put the numbers (one or two) in numbered and sealed envelopes (numbered from 1 to 20).

In each group, patients were compared to detect a difference in patency, volume, intracavitary fluid in the sagittal plane (mm), and instillation pressure when using gel or saline.

Subsequently, the two groups were compared to evaluate if there was a difference by first using gel or saline.

Descriptive statistics were performed with R Studio (R Foundation for Statistical Computing, Vienna, Austria) and GraphPad Prism v5.01 (GraphPad Software, La Jolla California, USA), applying the Wilcoxon Signed Rank test for quantitative and McNemar test for binary outcomes.

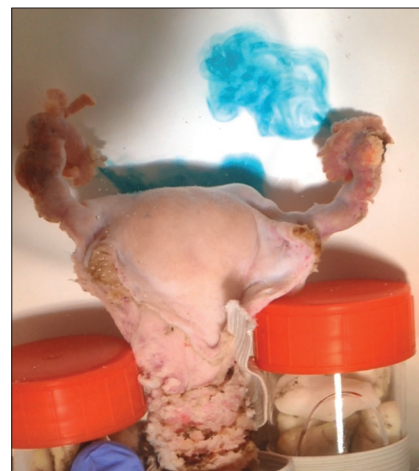All procedures were carried out with the same equipment and by the same investigators. In the operation room, the hysterectomy specimen was immediately placed in a container with warmed (at 36°C) Plasmalyte® and kept in an isothermal box. The temperature of these isotonic solutions was between 30°C and 37°C using the heating oven (Memmert®). The examination was performed at the ultrasound department within 1 h after the surgical procedure.

Before starting the procedure, 0.1 ml green ink (Waterman® Harmonious Green Ink) was equally mixed with 20 cc of saline (BD PosiFlush™ SP NaCl 0,9%) (Becton Dickinson, Eynsins, Switzerland) and 0.1 ml blue ink (Waterman® Serenity Blue Ink) was mixed with 20 cc of Endosgel® (FARCO-PHARMA GmbH, Cologne, Germany). For the measurement of the ink volume, a U-100 insulin syringe was used. The saline and the gel were warmed to a temperature between 30°C and 37°C.

To maintain uterine submersion, the uterus was fixed with an elastic band attached to little jars filled with small pebbles [Figure 1]. Hereafter, the uterus was placed in Plasmalyte® during the whole procedure to respect the physiology as much as possible.<sup>[18,19]</sup>

First, an underwater ultrasound examination was performed to check the presence of pre-existing fluid in the uterine cavity. In case there was some liquid inside, this was removed by aspiration with a Pipelle® catheter (CooperSurgical, Inc., Venlo, Netherlands).

Second, a uVue® (Cook Medical) balloon catheter was inserted into the uterine cavity. The balloon was filled with



**Figure 1:** Study setup

1-cc saline. The fluid instillation was performed by the first author (ST).

Depending on the randomization, saline (group one) or gel (group two) was used first to fill the uterine cavity. For the fluid instillation a 5-cc syringe was used. The instillation was continued until bilateral tubal patency was noticed or till a maximal volume of ten cc was used.

As soon as tubal patency was noticed, the instillation volume was recorded.

A subjective score between 1 and 10, indicating the pressure necessary to fill the uterus, was also recorded.

Next, the maximal diameter of the fluid in the uterine cavity was measured in the sagittal plane. This measurement was recorded as soon as tubal patency was noticed or at the end of the instillation in the absence of patency.

If applicable, the possible anatomical reason for the absence of tubal patency was described.

Subsequently, the balloon catheter was removed to let the fluid leak out of the uterine cavity. If needed the remaining fluid was aspirated by a Pipelle® catheter. Underwater ultrasonography was performed to confirm that the uterine cavity was empty.

Third, these steps were repeated with gel (group two) or with saline (group one), according to the randomization. If needed the isotonic solution in the bucket was changed to keep the solution clear.

Two-dimensional images and three-dimensional volumes were pre-, per- and post-procedurally rendered by the second author (RH) (GE Voluson E10 Expert, GE Medical Systems, Zipf, Austria).

After completing these steps, the tissue was sent to the laboratory for routine anatomopathological research. Before the start of this study, it had been ascertained that the ink used did not interfere with the anatomopathological examination. Because after the inclusion of 15 patients one of the principal investigators (ST) was no longer available to perform the tests, we decided to stop further inclusions to maintain correct results and avoid confounders.

## RESULTS

Of the 15 patients, seven were randomized to group one (saline first) and eight to group two (gel first).

The reason for hysterectomy was presence of myoma(s) ( $n = 9$ ), BRCA 1 mutation ( $n = 2$ ), cervical intraepithelial neoplasia 3 ( $n = 1$ ), hereditary nonpolyposis colorectal cancer ( $n = 1$ ), ovarian mass ( $n = 1$ ), and adenomyosis ( $n = 1$ ).

In total, unilateral or bilateral tubal patency was noticed in eight cases with saline (53.3%) and in two cases with gel (11.1%). McNemar's Chi-squared test for the comparison of the resulting patency among the two instillation types, showed apparent favor of gel

instillation ( $P = 0.008$ ), with an odds ratio (OR) of 4.88 (95% confidence interval between 0.88 and 39.28) [Figure 2].

Concerning randomization versus patency, in group one, patency was seen five times with saline (71.4%) and once with gel (14.2%). In group two, patency was noticed three times with saline (37.5%) and once with gel (12.5%) [Figure 3].

The mean cavitory expansion after an instillation volume of 5 cc was equal for saline and gel (10 mm). After instillation of 10 cc, only a little difference in mean expansion was noticed, resulting in noninferiority and possibly even a trend in favor of gel [Figure 4].

The median volume necessary to show patency was 5 cc with saline versus 6 cc with gel.

The lowest instillation volume necessary to notice patency was 2 cc in the saline group, whereas in the gel group, patency could only be evidenced if at least 5 cc was injected [Figures 5 and 6].

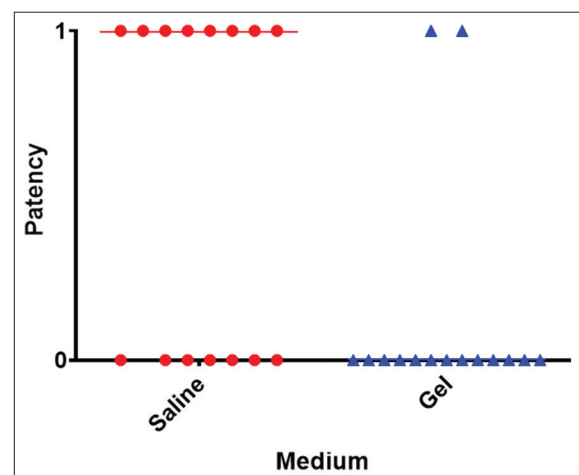
Regarding the subjective instillation pressure during saline infusion sonography and gel instillation sonography, higher pressure is needed during gel instillation sonography [Figure 7] ( $P < 0.001$  applying Wilcoxon's Signed Rank test).

The possible reason for the absence of tubal patency was checked and described in Table 1.

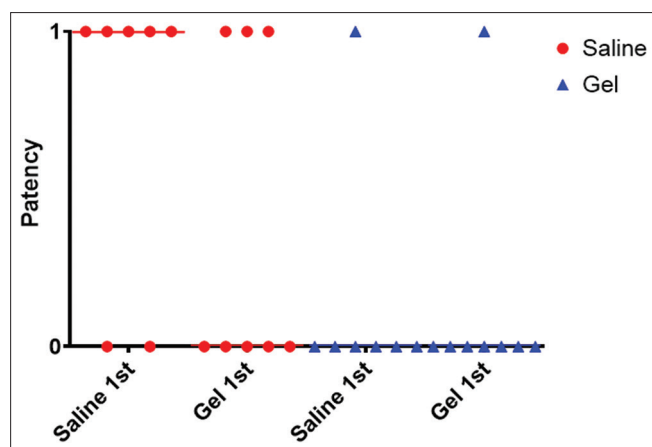
## DISCUSSION

This study is the first randomized controlled *in vitro* trial comparing tubal patency during saline versus gel instillation, demonstrating lesser patency and hence, a possible reduced risk for transtubal cell seeding during gel instillation.

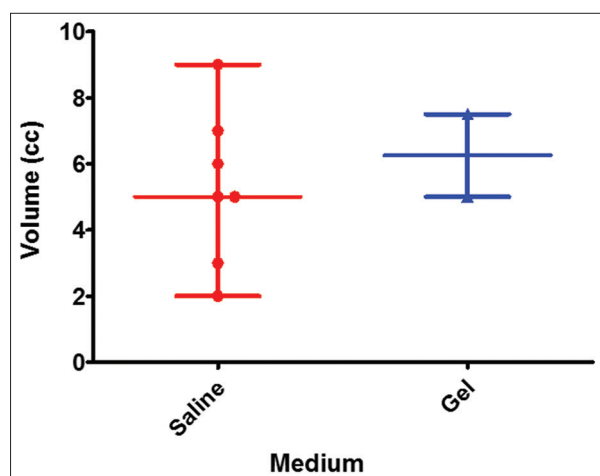
Our data show that transtubal flow is less likely with gel instillation sonography than with saline infusion sonography. Consequently, the hypothesis that lower fluid viscosity could cause more transtubal flow seems to be correct.



**Figure 2:** Binary outcome graph comparing tubal patency between saline and gel



**Figure 3:** Binary dot graph comparing the occurrence of tubal patency between the fluid types accounting for their respective timing of instillation



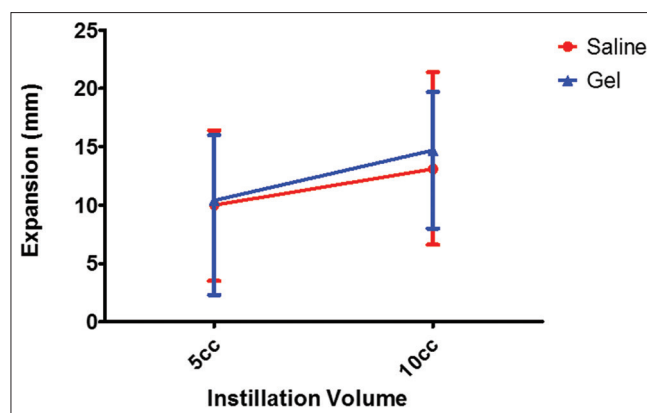
**Figure 5:** Graph summarizing the observed volumes resulting in tubal patency

The trend toward reduced patency in those randomized to “gel first” may be caused by a transient blocking effect of gel within the tubes.

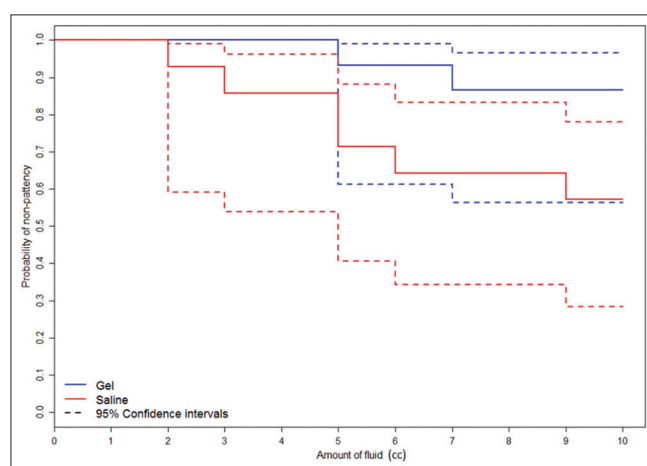
The lowest instillation volume necessary to notice patency was 2 cc in the saline group, whereas in the gel group, patency could only be evidence if at least 5 cc was injected.

In clinical practice, the instillation of gel up to 3 cc is generally enough to rule out focal intracavitary disease. In contrast, a higher volume of saline is often necessary to obtain a sufficient distention of the uterine cavity. In literature, the average instillation volume of saline varies between 5 and 20 cc.<sup>[20,21]</sup>

Owing to its viscosity, instillation pressures were perceived as significantly higher when using the gel as directly as compared to that of saline. This allows for lower infusion velocities, better control over cavitory pressure build-up and superior maintenance of minimally required dilation. A lower instillation velocity precludes rapid unintentional intracavitary volume expansion and hence reduces the risk for higher transtubal flow volumes.



**Figure 4:** Graph comparing observed cavitory expansion at predefined instilled volumes



**Figure 6:** Kaplan-Meier curve comparing probability of nonpatency among the two fluid types with respect to the infused volumes

Although there is no evidence so far demonstrating a correlation between positive peritoneal cytology, caused by diagnostic hysteroscopy or saline infusion sonography, and the prognosis of patients with endometrial cancer, transtubal cell seeding remains a matter of concern. Therefore, out of precaution, hysteroscopy guidelines advocate to use the lowest possible intrauterine pressure and the smallest volume necessary to achieve the diagnosis.

To minimize risks, we suggest using gel instead of saline infusion or diagnostic hysteroscopy as the first test in the diagnosis of intracavitary uterine lesions, including cancer. Our data show that using a maximum instillation volume of 4 cc gel, the risk of transtubal flow is minimal.

The principal strength of this study is randomization. Furthermore, the instillations and sonographic examinations were always performed by the same persons to avoid interobserver variability.

The principal limitation concerns the small series, which is expressed in the large confidence interval of OR when looking to tubal patency versus medium (saline/gel). Therefore, our findings should be confirmed in larger series.



**Figure 7:** Graph depicting instillation pressure assigned by a dedicated examiner on a scale from 0 to 10

**Table 1: Randomization during instillation procedure and reasons for hysterectomy and possible reasons of absent tubal patency**

Reason for hysterectomy	Randomization	Reason for the absence of tubal patency
Myoma (menorrhagia)	1	N/A
Myoma	2	N/A
HNPCC	1	no anatomical reason
BRCA1	2	N/A
Myoma (menorrhagia)	1	Myomatous uterine obstruction
Myoma (menorrhagia)	2	N/A
Ovarian mass	2	Cervical insufficiency
Myoma (menorrhagia)	2	Myomatous/gel-based uterine obstruction
CIN3	1	N/A
BRCA1	1	N/A
Myoma (menorrhagia)	1	N/A
Myoma (menorrhagia)	2	Myomatous/gel-based uterine obstruction
Adenomyosis	1	N/A
Myoma (menorrhagia)	2	Myomatous/gel-based uterine obstruction
Myoma (menorrhagia)	2	Myomatous/gel-based uterine obstruction

HNPCC: Hereditary nonpolyposis colorectal cancer, CIN: Cervical intraepithelial neoplasia, N/A: Not available

Another restriction is that different uterine pathology may interfere with patency. In the past, many hysterectomies were performed for dysfunctional bleeding or intrauterine lesions such as endometrial polyps. Nowadays, with the advanced hormonal therapy options and operative hysteroscopy, a hysterectomy is rarely the treatment of choice if the uterine cavity is intact, but rather in cases of intramural fibroids or adenomyosis. Therefore, we did not exclude uterine leiomyomas.

## CONCLUSION

The current data suggest that gel instillation has a safer profile as to the risk of transtubal flow and hence a possible reduced risk for transtubal cell seeding. Gel instillation sonography may, therefore, prove to be the diagnostic test of choice in women with abnormal uterine bleeding. However, as this is an *in vitro* trial and *in vivo* studies in larger series are necessary to confirm these results.

## Financial support and sponsorship

Nil.

## Conflicts of interest

There are no conflicts of interest.

## REFERENCES

1. de Kroon CD, de Bock GH, Dieben SW, Jansen FW. Saline contrast hysterosonography in abnormal uterine bleeding: A systematic review and meta-analysis. *BJOG* 2003;110:938-47.
2. Exalto N, Stappers C, van Raamsdonk LA, Emanuel MH. Gel instillation sonohysterography: First experience with a new technique. *Fertil Steril* 2007;87:152-5.
3. Van den Bosch T, Betsas G, Van Schoubroeck D, Daemen A, Vandenbroucke V, Cornelis A, *et al.* Gel infusion sonography in the evaluation of the uterine cavity. *Ultrasound Obstet Gynecol* 2009;34:711-4.
4. Werbrouck E, Veldman J, Luts J, Van Huffel S, Van Schoubroeck D, Timmerman D, *et al.* Detection of endometrial pathology using saline infusion sonography versus gel instillation sonography: A prospective cohort study. *Fertil Steril* 2011;95:285-8.
5. Bij de Vaate AJ, Brölmann HA, van der Slikke JW, Emanuel MH, Huirne JA. Gel instillation sonohysterography (GIS) and saline contrast sonohysterography (SCSH): Comparison of two diagnostic techniques. *Ultrasound Obstet Gynecol* 2010;35:486-9.
6. van Hanegem N, Breijer MC, Stockers SA, Zafarmand MH, Geomini P, Catshoek R, *et al.* Diagnostic workup for postmenopausal bleeding: A randomised controlled trial. *BJOG* 2017;124:231-40.
7. Epstein E, Ramirez A, Skoog L, Valentin L. Transvaginal sonography, saline contrast sonohysterography and hysteroscopy for the investigation of women with postmenopausal bleeding and endometrium >5 mm. *Ultrasound Obstet Gynecol* 2001;18:157-62.
8. Khan F, Jamaat S, Al-Jaroudi D. Saline infusion sonohysterography versus hysteroscopy for uterine cavity evaluation. *Ann Saudi Med* 2011;31:387-92.
9. Alfhaifi F, Ewies AA. The first-line investigation of postmenopausal bleeding. *Int J Gynecol Cancer* 2009;19:892-5.
10. Erdem M, Bilgin U, Bozkurt N, Erdem A. Comparison of transvaginal ultrasonography and saline infusion sonohysterography in evaluating the endometrial cavity in pre- and postmenopausal women with abnormal uterine bleeding. *Menopause* 2007;14:846-52.
11. Dessole S, Rubattu G, Farina M, Capobianco G, Cherchi PL, Tanda F, *et al.* Risks and usefulness of sonohysterography in patients with endometrial carcinoma. *Am J Obstet Gynecol* 2006;194:362-8.
12. Arikan G, Reich O, Weiss U, Hahn T, Reinisch S, Tamussino K, *et al.* Are endometrial carcinoma cells disseminated at hysteroscopy functionally viable? *Gynecol Oncol* 2001;83:221-6.
13. Polyzos NP, Mauri D, Tsiaras S, Messini CI, Valachis A, Messinis IE. Intraperitoneal dissemination of endometrial cancer cells after hysteroscopy: A systematic review and meta-analysis. *Int J Gynecol Cancer* 2010;20:261-7.
14. Guralp O, Kushner DM. Iatrogenic transtubal spill of endometrial cancer: Risk or myth. *Arch Gynecol Obstet* 2011;284:1209-21.
15. Chang YN, Zhang Y, Wang YJ, Wang LP, Duan H. Effect of hysteroscopy on the peritoneal dissemination of endometrial cancer cells: A meta-analysis. *Fertil Steril* 2011;96:957-61.

16. Al-Talib A, Nezhat F, Tulandi T. The role of hysteroscopy in diagnosis and management of endometrial cancer. *Gynecol Surg* 2010;7:211-6.
17. Umrani S, Clark TJ, Saridogan E, Miligkos D, Arambage K, Torbe E, *et al.* BSGE/ESGE guideline on management of fluid distension media in operative hysteroscopy. *Gynecol Surg* 2016;13:289-303.
18. de Ziegler D, Bulletti C, Fanchin R, Epiney M, Brioschi PA. Contractility of the nonpregnant uterus: The follicular phase. *Ann N Y Acad Sci* 2001;943:172-84.
19. Luyten T, Bultynck G, Parys JB, De Smedt H, Missiaen L. Measurement of intracellular  $\text{Ca}^{2+}$  release in intact cells using  $45\text{Ca}^{2+}$ . *Cold Spring Harb Protoc* 2014;2014:284-8.
20. Dijkhuizen FP, De Vries LD, Mol BW, Brölmann HA, Peters HM, Moret E, *et al.* Comparison of transvaginal ultrasonography and saline infusion sonography for the detection of intracavitary abnormalities in premenopausal women. *Ultrasound Obstet Gynecol* 2000;15:372-6.
21. El-Faissal Y, El Lithy A. Gel-instillation versus saline infusion during sonohysterography: Any advantages? *Middle East Fertil Soc J* 2015;20:6-10.